

* Example of Teaching Component

ADCFP 2012 Teaching Assignments

Didactic Lectures

May 7, 2012

I delivered a lecture utilizing power point slides on the topic of "Alginate Impressions and Stone Casts" for following course: ~~XXXXXXXXXX~~ Introduction to Dentistry, Summer 2012.

This was part of a series of lectures followed by a lab/practical experience given to pre dental undergraduate students from the ~~XXXXXXXXXX~~. Feedback was mainly positive and most students benefited a lot from the laboratory/ hands-on portion of this lecture. However, I could have lectured somewhat more slowly.

June 2 and June 3, 2012

I delivered a power point lecture on the topic of "Dental Anatomy 101" through the ASDA pre-dental workshop. This ASDA led program offers pre dental students from all over the nation the chance to experience the life of a dental student in a 2 day course. It offers lectures and sim lab activities. Feedback received from students and faculty was mostly positive for this assignment. I attempted to involve students to make the lecture more interactive and I also supplemented the lecture with a quiz in between slides to keep the students engaged.

October 1, 2012

I delivered a Powerpoint lecture on the topic of Dental Histology: Enamel, Dentin, Pulp and Cementum to first year dental students in the following course:

~~XXXXXXXXXX~~ Introduction to Operative Dentistry Fall 2012

I was also involved in this course as a teaching assistant and a regular bench instructor. Reviews were mostly positive regarding my teaching style, but I could have delivered the material more slowly.

Preclinical Instruction

Fall and Winter of 2012/2013

I am a bench instructor, and a guest lecturer, for the following preclinical first-year dental course: Restorative Dentistry Part 1 which includes: Introduction to Operative Dentistry, Dental Anatomy and Occlusion, Direct Amalgam and Composite Restorations.

As a bench instructor, I provided assistance to students on various tasks and requirements. This varied from preparing and restoring teeth to waxing of teeth and basic occlusion principles. Other responsibilities included helping to grade quizzes and to assess the work of students. Feedback received from students and faculty was extremely positive and very encouraging.

Clinical Instruction **Summer, Fall and Winter of 2012/2013**

For ten full days spread throughout the three semesters, I supervised third year dental students on their first emergency and radiology rotations. I was also able to provide mentorship and supervision to third year students at the Oral surgery department. My responsibilities included guiding them in obtaining materials, helping them to follow school protocols, and clinical advice on the course of treatment. Unofficial feedback from the students and faculty was positive.

Small Group Session **February 1, 2013**

I facilitated a small group discussion for [redacted] I presented an ethical dilemma and encouraged students and faculty to discuss the ethical principles involved for the various alternatives for resolving the dilemma. A healthy discussion with good participation occurred and feedback was mainly positive.

Ethical Dilemma

(Partial case here)

Dentistry can be practiced in many different venues such as schools, private practices, nursing homes, and hospitals. In an educational institution, dental students are taught to perform ideal treatment in an effort to produce the best prognosis for the patient. Students are constantly reminded by faculty that this may not be how you will practice once you graduate and enter private practice. We rely on the fact that the [redacted] will teach the fundamentals and make us competent clinicians. I did not realize the true meaning of what these private practice faculty members meant until most recently. My ethical dilemma took place while I was on one of my offsite community outreach rotations. The decisions and judgments made by the offsite doctor involved instruction to administration of treatment that was not ideal and questionable in judgment.

It was Monday morning, my first day at the offsite clinic. Dr. Offsite enters the practice rushing into his office and gives a brief orientation to the clinic, practice philosophy, and staff. I received my first patient, a middle-aged, African

Example of Assessment

Classroom Lecturer Evaluation

Date: May 7, 2012

Lecture Topic: Alginate Impressions and Stone Casts

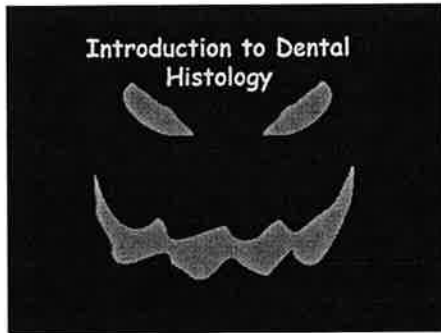
Please evaluate _____ as a lecturer by marking your level of agreement with the following statements. SA: Strongly agree, A: Agree, U: Undecided, D: Disagree, SD: Strongly disagree
N = 22

| | SA | A | U | D | SD |
|------------------------------------------------------------------|----|---|---|---|----|
| The lecturer identified the topic and objectives of the lecture. | 18 | 4 | 0 | 0 | 0 |
| The main points of the lecture were easy to understand. | 19 | 3 | 0 | 0 | 0 |
| The lecture was easy to follow with appropriate visual aids. | 19 | 3 | 0 | 0 | 0 |
| The lecturer related the information to clinical dentistry | 14 | 5 | 3 | 0 | 0 |
| The lecturer spoke clearly and at an appropriate pace. | 17 | 5 | 0 | 0 | 0 |
| The lecturer was able to answer questions. | 26 | 4 | 2 | 0 | 0 |

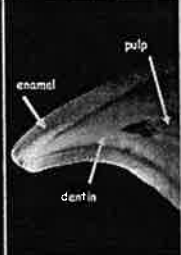
Comments:

- You are awesome and really good at explaining the techniques. Thank you!
- He was really good and helpful
- He was very good and made the lecture fun and I learned a lot
- Spoke very well and gave demonstrations
- He was awesome! Very nice and helpful
- _____ was very helpful with questions and didn't mind helping or teaching student one on one when they were struggling
- He is very helpful instructor and is easy to understand
- The only negative thing was that he kind of just read the slides to us. he was also very helpful in the lab
- He was very nice and helpful
- He was a great lecturer
- He was very helpful
- Helpful and ready with advice in the wet lab
- I really enjoyed this lecture today. Although my impressions weren't the greatest, this was definitely a learning experience
- Today's class went by very fast, very fun. Thanks for everything
- I enjoyed pouring up the models and _____ was very helpful when I needed direction
- I am glad that I got to experience a little bit of dentistry.
- He was very helpful
- He was very helpful. I think it is much easier to learn by watching and doing it yourself

Example of Presentation




Structures of the Tooth




- Hard tissues are mineralized (calcified) with hydroxyapatite (HAP) to different %
 - Enamel: 96%
 - Dentin: 70%
 - Cementum: 50%
- Soft tissue of the tooth is not mineralized
 - Pulp

Enamel




- Enamel rods and interrod enamel are composed of enamel crystals with some protein (amelogenin)
- No cells, blood vessels, or nerves in enamel
- No collagen
- Nonvital tissue that is not produced in an erupted tooth and cannot be repaired

The anatomical crown and the clinical crown



- The anatomical crown is the part of the tooth covered in enamel
- The clinical crown is the crown that is visible in the mouth
- As a person gets older, it is common for tooth enamel to be exposed above the gingiva and to have the root surface showing. This is called gingival recession.


The color of enamel



- Enamel is various shades of bluish-white
- It turns various shades of yellow-white because of the underlying dentin
- The enamel on primary teeth often appears whiter than on secondary teeth

Exposed dentin on tooth cusps

Dentinoenamel junction (DEJ)



- Zone where aprismatic enamel meets mantle dentin
- Area where tissues of different composition and function must join
- 30 μ m thick